

PRESENTING CLINICAL SIGNS

History: Grade 6/6 murmur, possibly continuous, noted 2 weeks ago. Murmur now grade 3-4/6.
Sedated for exam with butorphanol.

DATE

12/14/21

ECHOCARDIOGRAPHIC FINDINGS

2D, M-mode, and Doppler study.

PERFORMED BY:

Dr. Jacquie Pankatz

INTERPRETED BY

Keith Blass, DVM,
MS, DACVIM
(Cardiology)

Left atrial size is normal. The mitral valve is normal. Left ventricular wall thickness is normal. Left ventricular internal dimensions are normal. Left ventricular systolic function is normal. The subaortic region and aorta appear normal, though there is mildly increased flow velocity in this region (LVOT/Ao 2.37 m/s). The aortic valve appears normal, though very mild aortic insufficiency is present. Right atrial and right ventricular dimensions are normal. The tricuspid valve is normal. The pulmonary artery and pulmonic valve are normal. No shunting lesions are visualized. No pericardial effusion or cardiac masses are seen.

ECG during echo: Sinus rhythm

PATIENT

Hank Bennett

LA - 26.7 mm
IVSd - 8.6 mm
LVPWd - 8.8 mm
LVIDd - 27.4 mm
LVIDs - 17.6 mm
FS - 35.8%
RA - 21.1 mm
LVOT - 2.37 m/s
RVOT - 1.50 m/s

SPECIES

Canine

BREED

Rottweiler

ASSESSMENT/RECOMMENDATIONS

Hank's murmur appears to be due to the presence of increased flow velocity in his left ventricular outflow tract/aorta. While the velocity of flow is not high enough to be definitive for the presence of subaortic stenosis (SAS), Hank is only 14 weeks of age, therefore, it's possible that the lesion of this disease could first be developing and that his flow velocity could increase over the next year or so. Therefore, a recheck echocardiogram is recommended in 4-6 months. If Hank's flow velocity remains below 2.5 m/s, it would appear that his murmur is functional/innocent in nature, while a velocity above 2.5 m/s would be consistent with the presence of SAS.

AGE

14 wk

No therapy is recommended based on this exam.

WEIGHT

12.6 kg

HOSPITAL NAME

Mountain Vista VH

REFERRING VET

Dr. Pankatz



DATE

12/14/21

PERFORMED BY:

Dr. Jacquie Pankatz

INTERPRETED BY

Keith Blass, DVM,
MS, DACVIM
(Cardiology)

PATIENT

Hank Bennett

SPECIES

Canine

BREED

Rottweiler

SEX

M

AGE

14 wk

WEIGHT

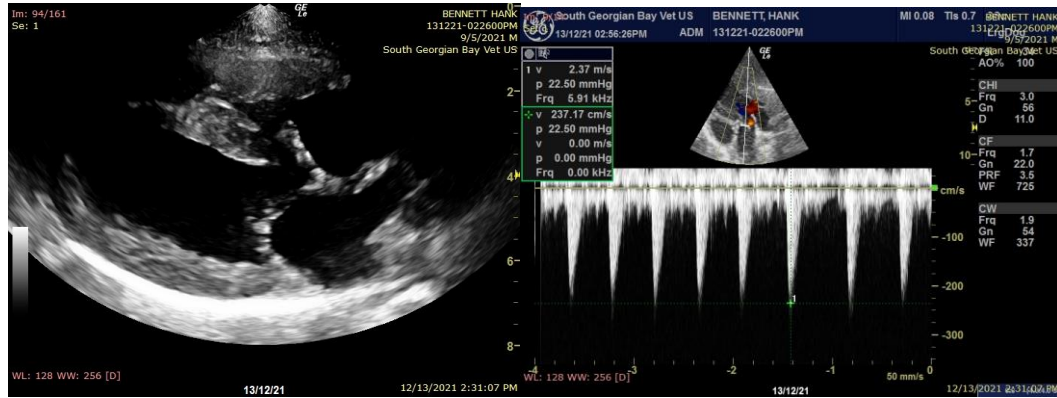
12.6 kg

HOSPITAL NAME

Mountain Vista VH

REFERRING VET

Dr. Pankatz



The information and recommendations provided are based on the images presented by the referring veterinarian. No evaluation can be communicated regarding pathology that was not visible in the image/video clips provided.

Thank you for this referral. If the clinical or image interpretation does not parallel your findings or if I can be of any further assistance please contact me.

Keith Blass, DVM, MS, DACVIM (Cardiology)
KeithBlass@gmail.com
631-804-5754